

# Is The Conservative Approach Effective To Manage Foreign Body Ingestion With Digestive Tract Anomaly Children

Sayanthan B<sup>1</sup> and Abeysunasekara S<sup>2</sup>

<sup>1</sup>Lecturer, Department of Surgery, University of Jaffna, Sri Lanka

<sup>2</sup>Consultant Paediatric Surgeon, Lady Ridgeway Hospital for Children, Sri Lanka

\*Corresponding author:

Sayanthan B

Department of Surgery, University of Jaffna, Sri Lanka,

E-mail: t.ranga13@gmail.com

Received Date: 28 Nov 2023

Accepted date: 12 Jan 2023

Published Date: 23 Jan 2023

## 1. Abstract

The phenomenon of foreign ingestion (FB) is considered as a commonplace state of affairs in kids and numerous management strategies are endorsed. This study assessed the efficient clinical consequences of a non-invasive interventional method for doing away with FB in a gastrointestinal tract abnormality young boy. The goal of this paper is to provide perception into the non-invasive therapeutic interventional approach to managing FB ingestion among children.

## 2. Keywords:

Foreign body ingestion, children, endoscopy, digestive tract anomaly guidelines

## 3. Introduction

The FB indigestion is a significant problem that causes morbidity and mortality in childhood children who are very keen to explore the environment by keeping the object in their mouths after the age of six months. Unfortunately, a number of these tiny objectives can be unintentionally swallowed and eventually this has resulted in increasing parental anxiety [1]. The gender distribution of FB ingestion is showed slightly male predominance between boys and girls as well as the high number of incidents is noted in the age range from 6 months to 3 years [2]. The majority of swallowed FBs are eliminated naturally through the gastrointestinal tract (GI) without causing any clinical complications although endoscopic and surgical approaches are required only in a few cases [3].

A recent research study found that 91.6% of FB ingestions were passed spontaneously while only 8.3% of cases required endoscopic removal [4].

Another study revealed that 80%–90% of particles were passed naturally through the GI tract without causing any complications while 10%–20% were removed by endoscopic procedures and there was only 1% required open surgery [5]. IJCMCR-v5-1002 In some ingested foreign body incidents, it cannot easily move through the part of GI tract like pylorus, stomach, duodenum and ileocecal valve [6]. This may become a complication in the case of GI tract anomaly [7]. Most of the time FB ingestion are transiently discomfort and after become symptomless or can be presented with mild irritation, even rarely causing life-threatening problem [8]. There is some factors influence the necessity of emergency removal of FBs including the type, shape, size and site [9]. The primary aim of this study was to assess the effectiveness of non-invasive management of FB ingestion in a GI tract anomaly. This will help to provide the clue for treating clinicians to manage the FBs ingestion in children.

## 4. Case Presentation

An 8 years old boy was transferred from a peripheral hospital to a tertiary clinical centre after 3 days of accidental ingestion of metal coin. The plain radiological image was taken at the peripheral hospital immediately after the admission. This children had undergone pyloromyotomy for infantile hypotrophic pyloric stenosis surgery when he was 2 years although the patient clinically had no complaints. There was no evidence of FB elimination spontaneously even after 5 days of the ingestion thus the patient transferred to the tertiary care centre to further management. After the transferring also the X-ray was taken and it showed that the metal coin located at the same position; pyloric antrum (Figure:1a). While was planning for the upper gastrointestinal endoscopy due to delay of spontaneous elimination and the past surgical history of GI tract abnormality, our earlier study non-invasive protocol was applied [4]. The X-ray was repeated at the 6<sup>th</sup> and it revealed that the coin was moved significantly (Figure:1b).

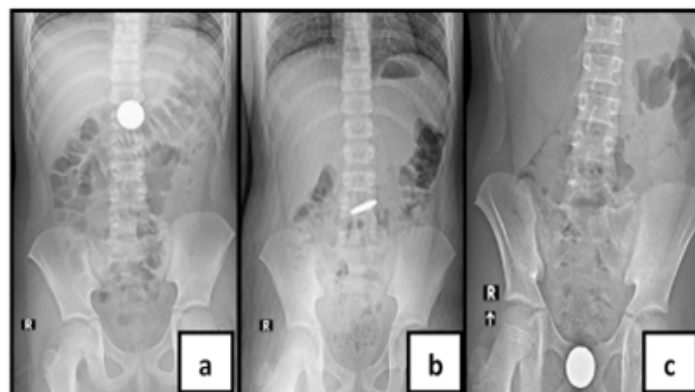


Figure 1: (a) X-ray 1st and 3rd day (b) day 6th (c) day 7th repeated X-ray

# Insights Journal Of Surgery And Clinical Case Reports

Therefore, the protocol was followed continuously while monitoring the movement of the coin by repeating the plain radiological image. At the day of 7<sup>th</sup>, the coin reached the distal part of GI tract (Figure:1c) and the coin was eliminated with the stools within two days after applying the non-invasive therapeutics intervention (Figure 2).



**Figure 1:** (a) X-ray 1st and 3rd day (b) day 6th (c) day 7th repeated X-ray

## 5. Discussion

The FB ingestion is one of the most frequent complaints of paediatric presenting to the paediatric clinical practice. In our previous study, most events occurred in children age ranging from 1 to 3 years whereas the mean age was  $5.18 \pm 3.1$  years and the median was 5 years. This study participant's gender distribution between boys and girls was 3:2. These similar findings are consistent with other gender distribution reports related to FB ingestion a research study showed slightly male predominance [5]. It is largely acknowledged that the high prevalence of FB ingestion is identified in children because of their exploratory habits despite involving the gender difference between males and females [10]. However, our previous study claimed that it is likely that 62.9% of incidents were reported in the presence of adults despite the aloneness (55.8%). Almost, 88.8% of FB ingestions cases were related to spontaneously passed with a stool and only 2.78% with vomiting but it was also found 8.3% of cases expressed endoscopy removal although most of cases (92.1%) were discharged within a day of the hospitalization [4]. Another study revealed that 80%–90% of particle were passed naturally through the GI tract without causing any complications while 10%–20% were removed by endoscopic procedures and there was only 1% required open surgery [11]. Because in some ingested phenomenon foreign body cannot easily move through the part of GI tract like pylorus, stomach, duodenum and ileocecal valve [8]. This may become a complication in the cases of GI tract abnormality [12].

The common type of swallowed FBs is radiopaque including coins, screws,

tiny magnets, safety pins, nails, plastic buttons and button batteries though the radiolucent object like food particle impaction is to be considered in the ingested management [13]. Most of the time FB ingestion are transiently discomfort and later become symptomless or can be presented with mild irritation, even rarely causing life-threatening problem [14]. There are some factors that influence the necessity of emergency removal of FBs including the type, shape, size and site [15]. FB ingestion is a potentially serious problem that peaks at a younger age. There are a number of studies conducted the management of this pathology relatively depends on the patient's age, developmental stage of children, the type of the ingested objects, and the clinical presentations [4] though our previous study findings postulated that the majority of FB ingestions can be passed spontaneously without causing clinical complications after applying the non-invasive therapeutic approach despite considering other factors such as age, gender, and type of FBs.

## 6. Conclusion

This case study provides the effectiveness of non-invasive management of FB ingestion in a GI tract anomaly. This will help to provide the clue for treating clinicians to manage the FBs ingestion in children.

## 7. Acknowledgments

The authors wish to thank, S.Thiruvaraman, Research Assistant who assisted to this piece of research paper preparation and submission process in the final stage of this article.

## References

1. Khorana J, Tantivit Y, Phiuphong C, Pattapong S & Siripan S. Foreign Body Ingestion in Pediatrics: Distribution, Management and Complications. *Medicina*. 2019; 55(10): 686.
2. Wood M, Potnuru P & Nair S. Inpatient Pediatric Foreign Body Ingestion: National Estimates and Resource Utilization. *Journal of Pediatric Gastroenterology & Nutrition*. 2021; 73(1): 37-41.
3. Diaconescu S, Gimiga N, Sarbu I, Stefanescu G, Olaru C, Ioniuc I, Ciongradi I & Burllea M. Foreign Bodies Ingestion in Children: Experience of 61 Cases in a Pediatric Gastroenterology Unit from Romania. *Gastroenterology research and practice*. 2016; 2016: 1982567.
4. Sayanthan B, Sanjaya A, Ganeshrajah A, Thiruvaraman S. A non-invasive novel approach for managing digestive tract foreign body ingestion in children. *Karnataka Paediatric Journal*. 2022; 37(1): 19-23.
5. Shamim A, Zuberi M & Shariff A. Laparoscopic retrieval

- of two intragastric spoons at least seven years after ingestion. *Laparoscopic, Endoscopic and Robotic Surgery*. 2019; 2(3): 77-79.
6. Bekkerman M, Sachdev A, Andrade J, Twersky Y & Iqbal S. Endoscopic Management of Foreign Bodies in the Gastrointestinal Tract: A Review of the Literature. *Gastroenterology Research and Practice*. 2016; 2016: 1-6.
  7. Tumay V, Guner OS, Meric M, Isik O & Zorluoglu A. Endoscopic Removal of Duodenal Perforating Fishbone - A Case Report. *Chirurgia (Bucharest, Romania :1990)*. 2015; 110(5): 471-473.
  8. Lee JH. Foreign Body Ingestion in Children. *Clinical endoscopy*. 2018; 51(2): 129-136.
  9. Lim C, Park M, Do H, Yeom J, Park J & Park E, et al. Factors Associated with Removal of Impacted Fishbone in Children, Suspected Ingestion. *Pediatric Gastroenterology, Hepatology & Nutrition*. 2016; 19(3): 168.
  10. Kramer R, Lerner D, Lin T, Manfredi M, Shah M & Stephen T. et al. Management of Ingested Foreign Bodies in Children. *Journal of Pediatric Gastroenterology & Nutrition*. 2015; 60(4): 562-574.
  11. Kramer R, Walsh C, Lerner D & Fishman D. Quality Improvement in Pediatric Endoscopy: A Clinical Report from the NASPGHAN Endoscopy Committee. *Journal Of Pediatric Gastroenterology & Nutrition*. 2017; 65(1): 125-131.
  12. Sugawa C. Endoscopic management of foreign bodies in the upper gastrointestinal tract: A review. *World Journal of Gastrointestinal Endoscopy*. 2014; 6(10): 475.
  13. Piotto L & Gent R. The value of ultrasound in the investigation of ingested foreign bodies in children. *Sonography*. 2018; 5(2): 51-60.
  14. Dereci S, Koca T, Serdaroglu F & Akcam M. Foreign body ingestion in children. *Türk Pediatri Arşivi*. 2015; 50(4): 234-240.
  15. Varga Á, Kovács T & Saxena AK. Analysis of complications after button battery ingestion in children. *Pediatric emergency care*. 2018; 34(6) 443-446.